

## ANTIHYPERLIPIDEMIC AND HEPATOPROTECTIVE ACTIVITY OF EXTRACTS OF *ZINGIBER CASSUMUNAR* RHIZOME, *GUAZUMA ULMIFOLIA* LEAVES, AND THEIR COMBINATION IN HIGH-FAT DIET-FED RATS

Nurkhasanah Mahfudh<sup>1</sup>✉, Nanik Sulistyani<sup>1</sup>, Ika D. Kumalasari<sup>2</sup>, Ananda K. Hilal<sup>1</sup>, Refliandi Refliandi<sup>1</sup>, Fezah Othman<sup>3</sup>, Zainul A. Zakaria<sup>4</sup>

<sup>1</sup>Faculty of Pharmacy, Universitas Ahmad Dahlan  
Yogyakarta, 55164, **Indonesia**

<sup>2</sup>Faculty of Industrial Technology, Universitas Ahmad Dahlan  
Yogyakarta, **Indonesia**

<sup>3</sup>Department of Biomedical Sciences, Faculty of Medicine and Health Sciences, Universiti Putra Malaysia  
Serdang, Selangor, **Malaysia**

<sup>4</sup>Department of Biomedical Science, Faculty of Medicine and Health Sciences, Universiti Malaysia Sabah  
Kota Kinabalu, Sabah, **Malaysia**

### ABSTRACT

Oxidative stress is related to several metabolic diseases, including hyperlipidemia. Previous studies have shown the antioxidant properties of *Zingiber cassumunar* rhizomes and *Guazuma ulmifolia* leaves. The objective of this study was to see how *Z. cassumunar* rhizomes, *G. ulmifolia* leaves extracts, and their combinations affect antihyperlipidemic and hepatoprotective activity in a high-fat diet-fed (HFD) rat. The water extract of *Z. cassumunar* rhizomes and *G. ulmifolia* leaves was evaporated in a freeze dryer to produce dry extracts. The Wistar rats were assigned into six groups at random: normal, positive, negative, *Z. cassumunar* rhizome extract at 400 mg/kg BW (ZC), *G. ulmifolia* leaf extract at 50 mg/kg BW (GU), and the combination of *Z. cassumunar* rhizome extract and *G. ulmifolia* leaf extract at (350+50) mg/kg BW (ZC+GU). The rats were fed HFD for 28 days, and the treatment groups also received the extracts for the last 14 days. The study revealed that ZC, GU, and ZC+GU significantly ( $p < 0.05$ ) reduced the levels of cholesterol and triglyceride when compared to the negative control. These treatments also showed a hepatoprotective effect by reducing the serum glutamic pyruvate transaminase (SGPT) and histopathological observation. The conclusion of the study showed that ZC, GU, and ZC+GU play an essential role in their antihyperlipidemic and hepatoprotective activities.

**Keywords:** antihyperlipidemic, extract, hepatoprotective, high fat diet, *Guazuma ulmifolia*, *Zingiber cassumunar*

### INTRODUCTION

Excess blood lipids, such as cholesterol, triglycerides, low-density lipoprotein (LDL), and low concentration of high-density lipoprotein (HDL), are important

signs to hyperlipidemia (Karam et al., 2017). Non-HDL cholesterol and the ratio of total cholesterol to HDL cholesterol are both good predictors of future

✉nurkhasanah@pharm.uad.ac.id, <https://orcid.org/0000-0001-6156-4318>

cardiovascular events (McLaughlin et al., 2017). Atherosclerotic cardiovascular disease (ASCVD), the leading cause of death, is caused by the buildup of plaque in the arteries (Khera et al., 2017). Atherosclerosis, a cardiovascular disease risk factor, could be caused by elevated levels of lipid in the blood (Nelson, 2013). LDL accumulation in the blood vessels due to a high-fat diet causes the modification of LDL to oxidized-LDL (Ox-LDL), resulting in oxidative stress (Amiya, 2016). Lipid peroxidation, protein oxidation, and DNA alterations are among the potential side effects of oxidative stress (Chen et al., 2012).

An elevated concentration of free fatty acids (FFA) leads to FFA transport and accumulation in the liver organ. The liver may get damaged as a result of accumulated fat. A previous study reported that a high-fat diet caused non-alcoholic fatty liver disease (Lian et al., 2020). Hepatic transaminases (SGPT and SGOT) that are held in the hepatocytes are released during liver injury and cause high levels in the blood (Zachariah et al., 2017). An increase in serum levels of the enzymes glutamic oxaloacetic transaminase (SGOT) and glutamic pyruvic transaminase (SGPT) indicates liver damage.

*Zingiber cassumunar* rhizomes and *Guazuma ulmifolia* leaves have been widely studied for their antioxidant potentials. The *in vitro* studies of *Z. cassumunar* showed strong antioxidant activity using 2,2-Diphenyl-1-picrylhydrazyl (DPPH) method with high content of polyphenolic compounds (Bua-In et al., 2009; Joram et al., 2018). The *in vivo* study reported an increase in antioxidant activity of hyperlipidemic rats treated by *Z. cassumunar* rhizomes extract at 200 and 400 mg/kg BW. Following treatment, the superoxide dismutase (SOD) activity was found to increase (Sari et al., 2020). *Z. cassumunar* rhizome extract also exhibits immunomodulatory activity by increasing the secretion of reactive oxygen intermediate (ROI) (Nurkhasanah et al., 2019). *G. ulmifolia* leaf extract also showed strong antioxidant activity *in vitro*, using various methods and showed the high content of flavonoids, phenolics, and tannins which contribute to the antioxidant activity (Rafi et al., 2020; Silva et al., 2010). The *in vivo* study of *G. ulmifolia* extract at a dose of 125 mg/kg BW reduces lipid peroxide by increasing SOD activity (Berenguer et al., 2007). The combination of *Z. cassumunar* and *G. ulmifolia* extract was carried out in the

total dose of 400 mg/kg BW to observe the effect of their combination in the same dose which previously proved to have antioxidant activity.

The aim of the study was to demonstrate the anti-hyperlipidemic and hepatoprotective of *Z. cassumunar* rhizomes, *G. ulmifolia* leaves extract, and their combinations in the high fat-diet induced rat by observing several parameters, including cholesterol, triglyceride, SGOT, SGPT levels, and the liver histopathologic profile. The combination of both extracts was expected to give better results and benefits in inhibiting hyperlipidemia, liver damage, and oxidative stress. The high-fat diet induction was reported to trigger hyperlipidemia (Lasker et al., 2019), thus a high-fat diet rat was used as a hyperlipidemia rat model.

## MATERIAL AND METHODS

### Study design

This experimental design of the study was posttest-only control-group design. The effectivity of the sample was compared statistically with a negative control group. And the effectivity of the high-fat diet model used was compared to a normal group which was given with standard feed.

### Plant material and extract preparations

The rhizomes and leaves of two plants, *Zingiber cassumunar* and *Guazuma ulmifolia*, were obtained from different locations in Indonesia. The plant materials were verified by the Biology Laboratory of Ahmad Dahlan, Yogyakarta, with identification number 239/Lab.Bio/B/X2020. The rhizomes were rinsed with water and chopped into pieces. The leaves were sorted and washed. Both samples were dried at 50°C in an oven (Sari et al., 2020) before being extracted using a distilled water solvent with a ratio of 1:5 (w/v) in a tiered pot for 30 minutes. The extract was concentrated after being evaporated in a vacuum rotary evaporator (Heidolph), followed by drying in a freeze dryer (Biobase).

### Animal

Thirty male Wistar rats weighing 150–250 g were used for the experiment. The rats were eight weeks old and were chosen to minimize hormonal impacts during the study. The rats were housed in a room with good

ventilation, a 12-hour light-dark cycle, and regulated humidity and temperature. All rats were acclimated to the new habitat for seven days prior to treatment. The study protocol was approved by the Research Ethics Committee of Universitas Ahmad Dahlan with approval reference 012009049.

### Material

The reagents used to detect cholesterol, triglycerides, SGOT, and SGPT were obtained from Diasys®. All other materials used for analysis were analytical-grade and were purchased from E Merck.

### Induction of hyperlipidemia in rats

The experimental rats were fed a high-fat diet (HFD) for 28 days, except the normal group, which were given only standard feed. The HFD was made by mixing 300 g of standard pellet (BR II), 20 g of chicken egg yolk, 100 g of butter, 10 g of beef fat, and 0.05 g of propylthiouracil (PTU) (Sari et al., 2020). The mixture was molded into pellets and dried. The rats were fed 15 g of HFD per day with ad libitum access to water. For the first 14 days, all groups received only HFD. For the remaining 14 days, the treatment group received HFD combined with the tested extracts. The comparison of nutrient content of standard feed and high-fat diet were presented in Table 1.

**Table 1.** The composition of nutrient in standard feed and high fat diet feed

Type of feed	Composition per 100 g			Total calorie
	carbohydrate	protein	fat	
BR II standard feed	60.5	19	4	354
High fat diet	43.37	17.09	51.30	455.44

### Experimental design

Thirty rats were randomly divided into six groups of five rats each. The groups were as follows:

Normal group    which was given standard feed  
 HFD group        which was given high-fat diet (HFD) feed

Positive control group    which was given HFD feed and NutriveBenecol, a cholesterol-lowering beverage, at a dose 1.8 mL/200 g body weight (BW) twice a day  
 ZC group                    which was given HFD feed and *Z. cassumunar* rhizome extract at a dose of 400 mg/kg BW  
 GU group                    which was given HFD feed and *G. ulmifolia* leaf extract at a dose of 50 mg/kg BW  
 ZC+GU group            which was given HFD feed and a combination of *Z. cassumunar* rhizome extract and *G. ulmifolia* leaf extract at a dose of 350:50 mg/kg BW.

The extracts were dissolved in 0.5% sodium CMC and given orally using a probe to ensure the dose of treatment was accepted by the test animal. The study used NutriveBenecol as the positive control because a previous study showed that it effectively reduced total cholesterol and LDL cholesterol in human subjects with hypercholesterolemia after two weeks of treatment (Lestiani et al., 2018). The bodyweight of the rats was measured every week for 28 days. The blood sample was taken from sinus orbitalis using a capillary pipe. On day 29, the animals were euthanized using carbon dioxide (CO<sub>2</sub>) (Canadian Council of Animal Care, 2010) and dissected to collect the liver organ.

### Measurement of cholesterol and triglyceride levels

Cholesterol levels were determined using the CHOD-PAP (Cholesterol Oxidase-Peroxidase Aminoantipyrene) method using a Diasys® kit. Measurement of triglycerides was carried out using the GPO-PAP (Glycerol Phosphate Oxidase-Para Aminophenazone) method using Diasys® reagent. The 10 µL of blood serum and 1000 µL of reagent were thoroughly mixed. After a 5 minutes incubation period at 37°C, the intensity was measured using a Shimadzu UV-1900 spectrophotometer at 546 nm.

### Measurement of SGPT and SGOT levels

Diasys® reagent was used to detect SGPT and SGOT levels, and the procedure was as described in the manufacturer's instruction. First, 100 µL of serum was

blended with 1000  $\mu\text{L}$  of Reagent 1, which was then incubated at 37°C for 5 minutes, and finally 250  $\mu\text{L}$  of Reagent 2 was added. The intensity of the mixture was quantified at 365 nm four times every minute. The effectivity of tested agents in liver protection was compared with the negative control and presented as a percentage of hepatoprotective effect (Mahfudh et al., 2022).

### Liver histopathology preparation

Following the dissection of the experimental animals, the liver organs were taken and cut into  $1 \times 1 \times 1 \text{ cm}^3$  size, fixed in 10% buffered formalin for 24 hours, and then put into a tissue cassette after the fixation was complete. The tissue cassette was inserted for dehydrating/clearing and embedding into the tissue processor. This study used paraffin blocks (for tissue blocking) trimmed with a microtome into 5–6  $\mu\text{m}$ . Next, a set of microscope slides was stained with hematoxylin-eosin (HE). The dried preparations covered with a cover glass were ready to be examined under a light microscope with 100 $\times$  magnification. The histopathological analysis was carried out from 3 animals from each group. Each organ was sliced into 6 different parts in each organ. The analysis was carried out by expert independence analysis.

### Statistical analysis

The data for total cholesterol, triglycerides, SGPT, and SGOT activities were analyzed using analysis of variance (ANOVA). The Least Significant Difference (LSD) test was used to compare the treatment outcomes between the groups, with a significance level of 95%. The statistical analysis was performed using SPSS software (version 22).

## RESULTS

### Effects of *Z. cassumunar* and *G. ulmifolia* extracts on body weight

Table 1 shows the initial weight, final weight, and weight gain in every week of the experimental animals. All tested rats gained body weight during the experiment, but HFD induced rats experienced significantly higher weight gain per week than normal groups ( $p < 0.05$ ). After receiving treatments in the last two weeks of the experiment, the groups receiving ZC,

GU, ZC+GU, or NutriveBenecol showed a reduction in weight gain, compared to the HFD group, which was a negative control, although there is no significance ( $p > 0.05$ ).

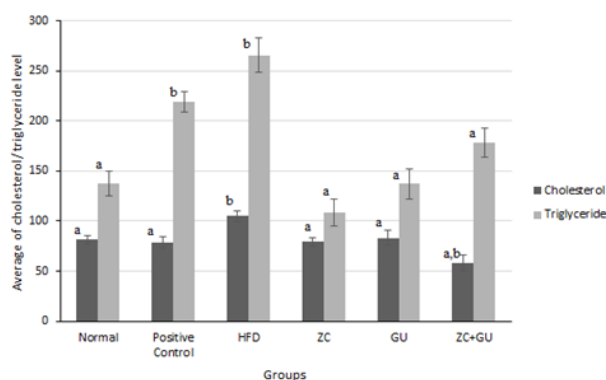
**Table 1.** Effects of *Zingiber cassumunar* and *Guazuma ulmifolia* extracts on weight gain caused by high-fat diets

Group	Initial body weight, g	Final body weight, g	Weight gain g/week
Normal	185.08 $\pm$ 22.17	193.48 $\pm$ 17.49	2.10 $\pm$ 0.53
Positive control	178.14 $\pm$ 9.94	199.82 $\pm$ 11.23	5.42 $\pm$ 2.55
HFD	175.80 $\pm$ 19.18	210.50 $\pm$ 18.33	8.68 $\pm$ 3.71 <sup>b</sup>
ZC	155.78 $\pm$ 5.64	178.33 $\pm$ 15.25	5.64 $\pm$ 2.83
GU	182.88 $\pm$ 18.62	203.42 $\pm$ 27.15	5.14 $\pm$ 2.72
ZC + GU	182.82 $\pm$ 18.80	201.28 $\pm$ 17.06	4.62 $\pm$ 2.88

b – significant change with the normal group ( $p < 0.05$ ).

### Effects of *Z. cassumunar* and *G. ulmifolia* extracts on cholesterol and triglyceride levels

The present study showed that induction of hyperlipidemia with 28 days of HFD increases the level of cholesterol and triglyceride significantly ( $p < 0.05$ ), compared to the normal group. Treatments with ZC

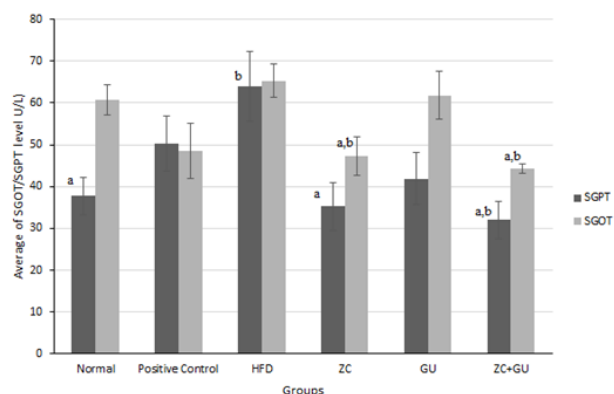


**Fig. 1.** Decreasing total cholesterol levels and triglyceride after treatments with *Z. cassumunar* rhizome and *G. ulmifolia* leaf extract in HFD-fed rats; data are presented as mean  $\pm$  SEM; a –  $p < 0.05$  compared to the negative control group; b –  $p < 0.05$  compared to the HFD group

(400 mg/kg BW), GU (50 mg/kg BW), and ZC+GU (350:50 mg/kg BW) were able to reduce the level of cholesterol and triglyceride significantly ( $p < 0.05$ ) in HFD-fed rats. Treatment with ZC+GU (350:50 mg/kg BW) was the most effective in lowering cholesterol levels, while the best triglyceride-lowering agent was ZC (400 mg/kg BW). This study only measured the total cholesterol and triglyceride, which could be a limitation of the study.

### Hepatoprotective effects of *Z. cassumunar* and *G. ulmifolia*

The current study found that HFD-induced hyperlipidemia in Wistar rats increased SGPT levels significantly ( $p < 0.05$ ), but the increase of SGOT is not significant ( $p > 0.05$ ) (Fig. 2). The increasing level of SGPT showed liver damage more specifically compared to SGOT, since the majority of SGPT was found in the liver, whereas SGOT could be found in other organs (Zachariah et al., 2017). The treatment with ZC (400 mg/kg BW) and ZC+GU (350+50 mg/kg BW) can reduce SGPT and SGOT levels significantly ( $p < 0.05$ ), compared to the HFD group, indicating the hepatoprotective potential of *Z. cassumunar*



**Fig. 2.** Effects of *Z. cassumunar* rhizome and *G. ulmifolia* leaf extract on SGPT and SGOT levels; data are presented as mean  $\pm$  SEM; HFD = high-fat diet; positive control = HFD + NutriveBenecol; ZC = HFD + *Z. cassumunar* extract at 400 mg/kg BW in a day; GU = HFD + *G. ulmifolia* extract at 50 mg/kg BW in a day; ZC + GU = HFD + *Z. cassumunar* and *G. ulmifolia* extract combination (350:50 mg/kg BW); a –  $p < 0.05$  compared to HFD group; b –  $p < 0.05$ , compared to the normal control

rhizome extract. The positive control (NutriveBenecol at 1.8 mL/200 g BW) did not exhibit a hepatoprotective. The previous study of NutriveBenecol showed a decrease in cholesterol and triglyceride in hypercholesterolemic patients (Lestiani et al., 2018).

The hepatoprotective effect of the treatments was compared with that of the negative control and presented as percentages (Table 2). The percentage of hepatoprotective effect reflects the effectiveness level of the treatment.

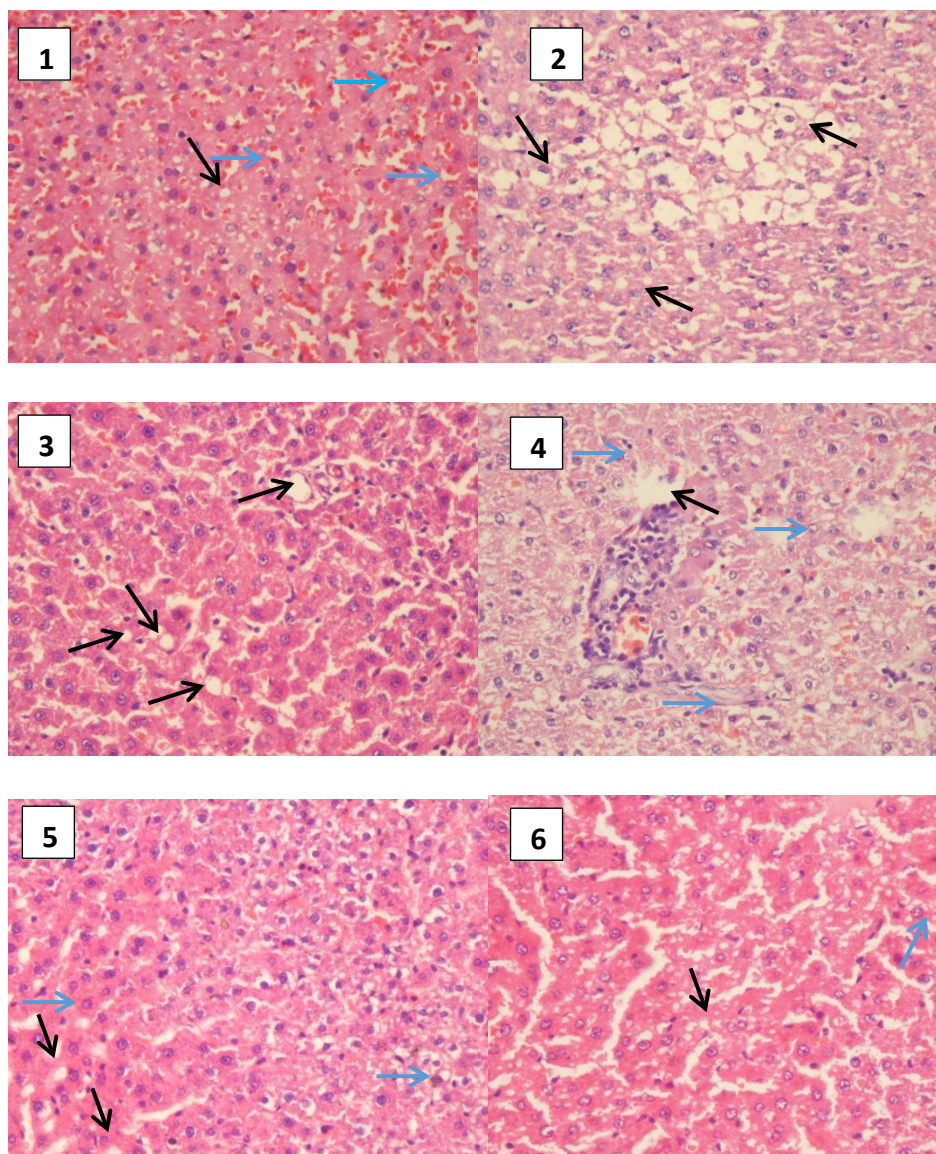
**Table 2.** Percentage of hepatoprotective effect of *Zingiber cassumunar* and *Guazuma ulmifolia* extracts on high-fat diet-fed rats

Groups	% hepatoprotection according to SGPT	% hepatoprotection according to SGOT
Positive	21.38	25.65
ZC	44.83	27.70
GU	34.49	5.41
ZC+GU	49.93	32.09

In the hepatoprotective effect test, ZC+GU had the highest protection among the other groups, according to SGPT and SGOT levels. The results showed that combining *Z. cassumunar* and *G. ulmifolia* extracts could accentuate the effectivity of each extract in protecting the liver against high-fat diet impacts. The histopathological observations of the liver in HFD-fed rats treated with ZC+GU are presented in Figure 3 (black arrow indicates fatty degeneration, blue arrow points to necrosis).

The histopathological observation (Fig. 3) showed droplets in some cells in the normal control group, as evident from the presence of fat vacuoles (Brunt, 2007). Furthermore, an increasing number of droplets was detected in the HFD group, potentially caused by fatty degeneration. Treatment of ZC and GU extract after HFD induction could reduce the number of droplets compared to the HFD control group, indicating the protective effect of ZC and GU in inhibiting fat accumulation in the liver organ.





**Fig. 3.** Histopathological description of the liver of test animals treated with a high-fat diet and a combination of *Z. cassumunar* rhizome and *G. ulmifolia* leaf extracts: (1) normal control; (2) HFD control; (3) positive control; (4) treatment with *Z. cassumunar* rhizome extract; (5) treatment with *G. ulmifolia* leaf extract; and (6) combination treatment with *Z. cassumunar* rhizome and *G. ulmifolia* leaf extracts. Black arrows show fatty degeneration, while blue ones indicate necrosis. The observation was carried out with 400× magnification.

## DISCUSSION

Hyperlipidemia has been reported to contribute to the development of degenerative diseases (Nelson, 2013). A high lipid level in the body enhances fatty acid

oxidation, increasing reactive oxygen species (ROS) levels (Sikder et al., 2018). Oxidative stress, which is caused by an imbalance between the production of reactive oxygen species (ROS) and the body's ability to neutralize them, is thought to be a major cause of

chronic disease (Mehta and Mehta, 2018). There are a number of ways to reduce ROS levels, including eating a healthy diet, exercising regularly, and avoiding smoking (Kilic and Cetin, 2018). Dietary interventions prove to be effective in decreasing cholesterol levels in hypercholesterolemia patients (Barkas et al., 2020).

The results have found that HFD increases the body weight of rats significantly ( $p < 0.05$ ) (Table 1), which is followed by increasing in a high lipid profile in the blood. A high-fat diet has been shown to increase the expression of HMG-CoA reductase in the liver organ and increase cholesterol synthesis (Thomas et al., 2012). Treatment with polyphenol-rich natural products is the quickest way to reduce cholesterol levels. Another study also reported that a high intake of fatty acid in HFD elevates cholesterol levels in the blood and liver (Dewi, 2019).

Furthermore, treatments with *Z. cassumunar*, *G. ulmifolia* extract, and their combination decreased the total cholesterol and triglyceride level significantly ( $p < 0.05$ ), compared to the HFD control. However, the ZC+GU combination did not give a better result than the single extract. This is because the combination affects the ability of each herb to decrease the lipid profile. However, Sukandar et al. (2012) reported that treatment with the *G. ulmifolia* at 25 mg/kg BW and turmeric (*Curcuma domestica*) at 12.5 mg/kg BW combination gives a better result compared to single ones.

*G. ulmifolia* contains high flavonoid and phenolic levels (Duraiswamy et al., 2018; Rafi et al., 2020), which are potentially responsible for its antioxidant and antihypercholesterolemic properties. The phenolic contents, including tannin, can lower cholesterol levels because of their ability to form micelles during the absorption process and their ability to reduce the absorption of cholesterol in the small intestine (De Jong et al., 2003; Acuff et al., 2007). Polyphenols can help to reduce the absorption of cholesterol from the gut, and they can also help to increase the excretion of cholesterol from the body (Bedoya-Martínez and Pineda-Hernández, 2014; Cai and Yang, 2016). Flavonoids suppress the formation of cholesterol in the liver through the inhibition of HMG-CoA reductase (Prahastuti et al., 2011) and ultimately prevent the atherosclerosis (Lei and Yang, 2020). *G. ulmifolia* is also rich in saponins, which can inhibit the activity of pancreatic lipase enzymes and, thus, reduce fat absorption in the intestine (Han et al., 2000). Tannins are compounds that can lower cholesterol levels by binding

and shrinking proteins through reactions with mucosal proteins and intestinal epithelial cells, inhibiting fat absorption (Sakaganta and Sukohar, 2021).

The active compounds of *Z. cassumunar* rhizome are phenylbutenoids, curcuminoids, and essential oils (Han et al., 2021). Curcumins can increase the expression of cholesterol-7 $\alpha$ -hydroxylase (CYP7A1), which turns cholesterol into bile acids before being excreted into the intestine (Han et al., 2021).

Excessive fatty acids in the blood and followed by accumulation in liver cells is a prerequisite for fatty degeneration (Dewi, 2019). The present study has also found that HFD-induced hyperlipidemia leads to elevated SGPT levels (Fig. 2), which has been shown in a previous study (Mahfudh et al., 2021). Besides an increase in SGPT level, liver damage can also be observed with liver histopathology (Fig. 3). The result showed that many droplets in the liver hepatocytes indicate fatty accumulation.

An imbalance between the liver's triglyceride production and secretion causes fatty liver, which is characterized by fat accumulation in the hepatocytes of the liver. Fatty droplets and necrosis were still found in the group treated with *Z. cassumunar* rhizome extract. The flavonoids contained in *Z. cassumunar* rhizome may contribute to the inhibition of fat accumulation in the liver. Curcumin, one of the chemical content found in *Z. cassumunar*, plays an important role in hepatoprotective effect. The previous study showed the effectiveness of curcumin in CCl<sub>4</sub>-induced hepatotoxicity (Ebaid et al., 2021).

The liver histopathological profile of the group treated with *G. ulmifolia* leaf extract showed a low fatty degeneration. Meanwhile, the group receiving the combination treatment experienced less cellular damage compared to the negative control group.

## CONCLUSION

The combination of *Zingiber cassumunar* rhizome and *Guazuma ulmifolia* leaf extracts decreases the cholesterol and triglyceride level by decreasing the total cholesterol level in high-fat diet rats. This combination also shows a hepatoprotective effect by reducing the SGOT and SGPT levels in high-fat diet rats. This finding suggests that the combination of two herbal medicines gives the better pharmacological effect.

## FUNDING SOURCE DECLARATION

This work was supported by the Ministry of Education, Culture, Research, and Technology through the Fundamental Research Excellence in Higher Education grant scheme, grant number 008/SK.PJD/LPPM/VII/2021.

## ACKNOWLEDGEMENT

The authors would like to thank the Ministry of Education, Culture, Research, and Technology for funding this study through the Fundamental Research Excellence in Higher Education grant scheme, with grant number 008/SK.PJD/LPPM/VII/2021.

## DATA AVAILABILITY

Datasets from the current study are available from the corresponding author upon request.

## DECLARATIONS

### Ethical Approval

The study protocol was approved by the Research Ethics Committee of Universitas Ahmad Dahlan with approval reference 012009049. The current study has been approved by the Research Ethics Committee.

### Competing Interests

The authors declare that they have no conflicts of interest.

### Open Access

This article is licensed under a Creative Commons Attribution 4.0 International License, which permits use, sharing, adaptation, distribution and reproduction in any medium or format, as long as you give appropriate credit to the original author(s) and the source, provide a link to the Creative Commons licence, and indicate if changes were made. The images or other third party material in this article are included in the article's Creative Commons licence, unless indicated otherwise in a credit line to the material. If material is not included in the article's Creative Commons licence and your intended use is not permitted by statutory regulation or exceeds the permitted use, you will need to obtain permission directly from the copyright holder. To view a copy of this licence, visit <http://creativecommons.org/licenses/by/4.0/>.

## REFERENCES

- Amiya, E. (2016). Interaction of hyperlipidemia and reactive oxygen species: Insights from the lipid-raft platform. *World J. Cardiol.*, 8(12), 689. <https://doi.org/10.4330/wjc.v8.i12.689>
- Barkas, F., Nomikos, T., Liberopoulos, E., Panagiotakos, D. (2020). Diet and cardiovascular disease risk among individuals with familial hypercholesterolemia: Systematic review and meta-analysis. *Nutrients*, 12(8), 1–22. <https://doi.org/10.3390/nu12082436>
- Bedoya-Martínez, M. L., Pineda-Hernández, E. (2014). Effect of dietary polyphenols on lipid metabolism. *Nutrients*, 6(6), 2263–2286.
- Berenguer, B., Trabadelo, C., Sánchez-Fidalgo, S., Quílez, A., Miño, P., De la Puerta, R., Martín-Calero, M. J. (2007). The aerial parts of *Guazuma ulmifolia* Lam. protect against NSAID-induced gastric lesions. *J. Ethnopharmacol.*, 114(2), 153–160. <https://doi.org/10.1016/j.jep.2007.07.019>
- Brunt, E. M. (2007). Pathology of fatty liver disease. *Mod. Pathol.*, 20, S40–S48. <https://doi.org/10.1038/modpathol.3800680>
- Bua-In, S., Paisooksantivatana, Y., Weimer, B. C., Chowpongpan, S. (2009). Essential oil and antioxidant *Zingiber montanum* (Koenig) Link ex Dietr. *Kasetsart Journal of Natural Sciences*, 43, 467–475.
- Cai, H., Yang, Y. (2016). Polyphenols and cardiovascular health: From bench to bedside. *Nutrients*, 8(11), 723.
- Canadian Council of Animal Care (2010). Canadian Council on Animal Care in science CCAC guidelines on: euthanasia of animals used.
- Chen, L., Hu, J. Y., Wang, S. Q. (2012). The role of antioxidants in photoprotection: A critical review. *J. Am. Acad. Dermatol.*, 67(5), 1013–1024. <https://doi.org/10.1016/j.jaad.2012.02.009>
- Dewi, E., (2019). Efek Diet Aterogenik Terhadap Gambaran Histopatologi Hati Mencit (*Mus musculus*). *Jurnal Sains Riset*, 8(1), 25–30.
- Duraiswamy, B., Singanan, M., Varadarajan, V. (2018). Physicochemical, phytochemicals and antioxidant evaluation of *guazuma ulmifolia* fruit. *Int. J. Pharm. Pharmaceut. Sci.*, 10(9), 9–13. <https://doi.org/10.22159/ijpps.2018v10i9.26778>
- Ebaid, H., Al-Tamimi, J., Habila, M., Hassan, I., Rady, A., Alhazza, I. M. (2021). Potential therapeutic effect of synthesized AgNP using curcumin extract on CCl<sub>4</sub>-induced nephrotoxicity in male mice. *Journal of King Saud University – Science*, 33(2), 101356. <https://doi.org/10.1016/j.jksus.2021.101356>



- Han, A. R., Kim, H., Piao, D., Jung, C. H., Seo, E. K. (2021). Phytochemicals and bioactivities of *Zingiber cassumunar* roxb. *Molecules*, 26(8), 1–18. <https://doi.org/10.3390/molecules26082377>
- Joram, A., Das, A. K., Mahanta, D. (2018). Evaluation of antioxidant and phenolic contents of *Zingiber montanum* (J. Koenig) Link ex Dietr.: A potential ethnomedicinal plant of Arunachal Pradesh, India. *Pleione*, 12(2), 255–264. <https://doi.org/10.26679/Pleione.12.2.2018>
- Karam, I., Yang, Y. J., Li, J. Y. (2017). Hyperlipidemia Background and Progress. *SM Atherosclerosis Journal*, 1(1), 1–8.
- Khera, A. V., Greenland, P., Aragam, S. (2017). Hypertriglyceridemia and cardiovascular disease: a scientific statement from the American Heart Association. *J. Am. Heart Assoc.*, 6(12).
- Kilic, U., Cetin, M. (2018). Reactive oxygen species and cardiovascular diseases: Pathophysiology and therapeutic targets. *Curr. Pharm. Des.*, 24(19), 3487–3500.
- Lasker, S., Rahman, M., Parvez, F., Zamila, M., Miah, P., ..., Alam, M. A. (2019). High-fat diet-induced metabolic syndrome and oxidative stress in obese rats are ameliorated by yogurt supplementation. *Sci. Rep.*, 9(20026), 1–15. <https://doi.org/10.1038/s41598-019-56538-0>
- Lei, X., Yang, Y. (2020). Vitexin and an HMG-Co A reductase inhibitor prevent the risks of atherosclerosis in high-fat atherogenic diet fed rats. *Journal of King Saud University – Science*, 32(3), 2088–2095. <https://doi.org/10.1016/j.jksus.2020.01.037>
- Lestiani, L., Chandra, D. N., Laitinen, K., Ambarwati, F. D., Kuusisto, P., Lukito, W. (2018). Double-blind randomized placebo controlled trial demonstrating serum cholesterol lowering efficacy of a smoothie drink with added plant stanol esters in an Indonesian population. *Cholesterol*, ID 4857473. <https://doi.org/10.1155/2018/4857473>
- Lian, C.-Y., Zhai, Z.-Z., Li, Z.-F., Wang, L. (2020). High fat diet-triggered non-alcoholic fatty liver disease: A review of proposed mechanisms. *Chem. Biol. Interact.*, 330(5), 109–199. <https://doi.org/10.1016/j.cbi.2020.109199>
- Mahfudh, N., Mantali, M. F., Sulistyani, N. (2022). The anti-hyperlipidemic effect of purple sweet potato leaf extract (*Ipomoea batatas* L.) and red yeast rice combination on hypercholesterol rats. *Indones. J. Pharm.*, 33(1), 93–99. <https://doi.org/10.22146/ijp.2115>
- Mahfudh, N., Sulistyani, N., Syakbani, M., Dewi, A. C. (2021). The antihyperlipidaemic and hepatoprotective effect of *Ipomoea batatas* L. leaves extract in high-fat diet rats. *Int. J. Public Health Sci. (IJPHS)*, 10(3), 558–564. <https://doi.org/10.11591/ijphs.v10i3.20777>
- McLaughlin, V. V., Buring, J. E., Ridker, P. M. (2017). Non-HDL cholesterol, apolipoprotein B, and risk of cardiovascular disease: a prospective study of women. *JAMA Cardiol.*, 2(1), 103–110. DOI:10.1001/jama.294.3.326
- Mehta, P., Mehta, P. (2018). Oxidative stress and cardiovascular diseases: Role of antioxidants. *J. Clin. Diagn. Res.: JCDR*, 12(11).
- Nelson, R. H. (2013). Hyperlipidemia as a risk factor for cardiovascular disease. *Prime Care*, 40(1), 195–211. <https://doi.org/10.1016/j.pop.2012.11.003>
- Nurkhasanah, N., Sulistyani, N., Ghifarizi, M. A. (2019). The effect of bangle (*Zingiber cassumunar* Roxb.) rhizome chloroform extract on nitric oxide and reactive oxygen intermediate secretions in vitro. *Adv. Health Sci. Res.*, 18, 43–47. <https://doi.org/10.2991/adics-phs-19.2019.9>
- Rafi, M., Meitary, N., Septaningsih, D. A., Bintang, M., Rafi, M. (2020). Phytochemical profile and antioxidant activity of *Guazuma ulmifolia* leaves extracts using different solvent extraction. *Indones. J. Pharm.*, 31(3), 171–180. <https://doi.org/10.22146/ijp.598>
- Sakaganta, I. A. R., Sukohar, A. (2021). Bay leaves (*Syzygium Polyanthum*) as reducing blood cholesterol levels. *Medula*, 10(4), 618–622. <https://doi.org/10.53089/medula.v10i4.146>
- Sari, N., Nurkhasanah, N., Sulistyani, N. (2020). The antioxidant effect of bangle (*Zingiber cassumunar*) rhizome extract on superoxide dismutase (sod) activity in hyperlipidemic rats. *Res. J. Chem. Environ.*, 24(1), 78–81.
- Sikder, K., Shukla, S. K., Patel, N., Singh, H., Rafiq, K. (2018). High fat diet upregulates fatty acid oxidation and ketogenesis via intervention of PPAR- $\gamma$ . *Cell. Physiol. Biochem.*, 48(3), 1317–1331. <https://doi.org/10.1159/000492091>
- Silva, A. C., Rodrigues, M. A., Silva, J. A. (2010). Antioxidant activity of *Guazuma ulmifolia* leaves. *Food Sci. Technol.*, 44(2), 389–393.
- Sukandar, E. Y., Nurdewi, Elfahmi (2012). Antihypercholesterolemic effect of combination of *Guazuma ulmifolia* Lamk. Leaves and *Curcuma xanthorrhiza* Roxb. rhizomes extract in wistar rats. *Int. J. Pharmacol.*, 8(4), 277–282. DOI: 10.3923/ijp.2012.277.282
- Thomas, J., Shentu, T. P., Singh, D. K. (2012). Cholesterol: biosynthesis, functional diversity, homeostasis and regulation by natural products. In: D. Ekinici (ed.), *Biochemistry* (pp. 419–442). <https://doi.org/10.5772/32538>
- Zachariah, S. K., Paul, V., Mathews, K. S., Gopinath, J., Celine, T. M., Rajeeve, S. (2017). Hepatic transaminases as predictors of liver injury in abdominal trauma. *Int. Surgery J.*, 5(1), 181–186. <https://doi.org/10.18203/2349-2902.isj20175891>

